

MODIFIED SUTURELESS OPERATION FOR MILD BLEPHAROPTOSIS REPAIR

Ming Chen, MD, MSc, F.A.C.S.
University of Hawaii/ John a. Burns School of Medicine
UNITED STATES OF AMERICA

ABSTRACT

Purpose: To demonstrate a new modified technique and present the long term efficacy and safety in mild ptosis repair.

Methods: This modified technique included operations on 62 eyes of 47 patients over a 10-year period. Surgery was performed in a manner similar to a previously described technique; however, cautery rather than suture or sealant was utilized for wound closure.

Results: Of the 62 eyes included in this study, good lid position, which was defined as MRD1 (Margin Reflex distance to upper lid) above 4mm, was obtained in 59 eyes (95.1%, figure 2). The mean pre-operative MRD1 was 0.66 mm (range 0-2mm). The mean post-operative MRD-1 was 3.35mm (ranging from 2-4 mm) with a mean improvement of 2.69 mm (Table 3). The remaining three eyes demonstrated improvement in lid position, though not to the desired extent. Postoperatively, all eyes appeared symmetrical. Symmetry was defined as MRD1 of each eyelid within 0.5 mm. The follow-up period varied from one week to 10 years. No major complications, including entropion, tarsal buckling or wound dehiscence were observed. In one case, slight pain and irritation from a mild abrasion were noted on the day following the procedure.

Conclusion: The new modified technique is totally sutureless without using any sealant was faster, safer and economical compared to those literature described technique to treat mild blepharoptosis. In addition, the extended follow-up of this study supports this procedure's long-term efficacy.

Keywords: Blepharoptosis, Ptosis, Fasanella-Servat, Sutureless, sealant.

INTRODUCTION

Blepharoptosis is defined as a condition in which the eyelid rests below its normal position consequently can affect vision and appearance.¹ It can be seen with both congenital and acquired abnormalities. Congenital causes include Marcus Gunn jaw-winking syndrome, developmental myopathy of the levator muscle and blepharophimosis syndrome. Acquired causes include aponeurotic ptosis, myasthenia gravis, Horner's syndrome and third nerve palsy.¹ This particular modified technique focuses on patients with a Marginal Reflex Distance-1 (MRD-1) of 0-4 mm of acquired mild blepharoptosis with adequate levator function. This type of ptosis often is related to advanced age especially in Asian elderly. However, disinsertion also can result from multiple etiologies such as trauma, pregnancy, Graves' disease, and ocular surgeries such as glaucoma, cataract and retina surgery.¹ Of the various forms of acquired ptosis, the aponeurotic variant, which results from the partial dehiscence or disinsertion of the levator aponeurosis from the tarsal plate, is the most common.² It also has been suggested that long-term use of hard contact lenses may contribute to this form of ptosis.³

LITERATURE REVIEW

Fasanella and Servat first proposed a levator resection procedure for minimal ptosis in 1961.⁴ In 1969 the procedure began to grow in popularity, when Beard demonstrated that effective correction of minimal ptosis could be achieved by resecting the tarsus and Muller's muscle.⁵ However, the sutures that were used had the potential to induce severe corneal abrasions.⁶ In 1977 Luring proposed the notion of a sutureless version of the operation.⁶ In his procedure, the tarsus was clamped with two curved hemostats. Resection then was performed in the resulting groove, followed by applying antibiotic ointment and a pressure patch without cautery. He theorized that a suture was not needed since the levator muscle can function as a "natural biologic suture."⁶ Desirable corrections were achieved in 11 out of 12 cases (92%). In 1992 Gupta and colleagues conducted a study using a similar sutureless technique. Success was achieved in 94% of cases for mild ptosis.⁷ No notable complications were observed. Additionally, the study claimed that symmetry was improved by using a single long-curved hemostat instead of the two thin-curved hemostats employed in Luring's technique. The only notable complication was mild entropion, seen in 10% of cases. Foster et al. in 2006 published their retrospective chart review of 53 case series using fibrin sealant with 98% success rate without any notable complication.⁸ Czyz et al. in 2011 published their favorable results on the effectiveness of using a fibrin sealant in place of sutures for the Fasanella-Servat procedure compare to suture cases.⁹ In contrast to the findings of Luring and Gupta; this study claimed that a fibrin sealant was necessary in the sutureless operation to prevent complications such as tarsal buckling, wound dehiscence and under correction. No major complications were observed in the Czyz sutureless procedure, while the traditional variant of Luring's technique had a 17% complication rate. Although effective, the authors acknowledged that the use of the fibrin sealant included disadvantages. The most significant of these is the sealant's typical cost of \$150.00. Additionally, the sealant is a human product and therefore carries a "minute but potential risk of disease transmission" from blood-borne pathogen.

Since both Luring and Gupta used sutures for traction to the lid in their so call "sutureless procedure", Foster and Czyz both using sealant for their procedure; our trial sought to use cautery and examine the efficiency, efficacy and safety of the modified sutureless Fasanella-Servat procedure without the use of any suture or fibrin sealant. Instead, meticulous bipolar cautery was used to seal the wound and stop any bleeding. The technique can reduce the surgical time, risks and cost of the procedure. The advantages of this trial over the previous research include a maximum follow-up of 10 years and the involvement of a higher number of cases.^{6,7}

Despite all the benefits of this procedure, it also shares some disadvantages of Fasanella-Servat procedure. The basic lacrimal secretors are excised and can cause or aggravate keratitis sicca. Too much loss of conjunctiva from the superior fornix can lead to entropion. Therefore, this procedure should be avoided in patients with cicatricial conjunctival disease, such as pemphigoid, conjunctival scarring, lymphoma and trachoma. Keratitis sicca should be a contraindication since conjunctival tissue, including accessory aqueous glands, is excised. More than 3 mm of tarsus should not be excised in this procedure to avoid tarsal buckling.

TECHNIQUE

The procedure begins with the eversion of the eyelid to expose the superior fornix. A single cc of 2% Xylocaine with epinephrine is injected into the conjunctiva for anesthesia and

hemostasis. Two fine-curved hemostats are used to clamp the tarsus and Muller's muscle for at least 60 seconds at the marking where the desired tissue for excision has been delineated. The points of clamps should meet at a level that is approximately above the pupil or at the position where the highest point of the eyelid arch is desired. Tissue was excised according to the following ratios: 1 mm tarsus excision for 2 mm of ptosis correction and 2 mm conjunctiva Muller's muscle excision for 1 mm of ptosis correction. Thus, 3 mm of correction could be obtained by resecting 1 mm of tarsus and 2 mm of conjunctiva Muller's muscle. The exact amount of excised tissue varies considerably among studies. In one study the surgeon elected to use the specific ratio of 2 mm tarsus=1 mm correction.¹⁰ However, others excised a set amount, regardless of the degree of ptosis.¹¹ With the clamps in place for one minute, and the clamps were checked for its tightness, the desired tarsus, Muller's muscle and conjunctiva are excised with #15 blades. The edge of the wound is trimmed carefully with scissors. Meticulous bipolar cauterization is performed at the wound to ensure no bleeding occurs. Once complete, one clamp is removed, and the wound is checked to see if additional cautery is needed. The first clamp is replaced, and tissue from the other side is excised and cauterized in the same manner. Bleeding is checked again, and additional cautery is applied as needed after the clamp is removed. The entire procedure often is completed in five minutes. Tobramycin/dexamethasone ophthalmic ointment is applied at the end of the surgery, and a pressure patch is placed over the eyelid for one day. This modified procedure is totally sutureless and does not require fibrin sealant as compare to the versions proposed by Lauring, Gupta, Foster and Cxyz.

Surgical video can be viewed on youtube.com: search "Chen's total sutureless, fast drooping lid repair" and Eyetube.net: search at oculoplastic section for Chen's Modified Sutureless Fasanella-Servat Operation for mild Blepharoptosis Repair

METHODOLOGY

Charts of patients who were included in this modified sutureless Fasanella-Servat procedure from February 2004 to August 2014 were reviewed for complication and surgical result. All surgeries were performed by Dr. Ming Chen at a single surgical center in Honolulu, Hawaii. Preoperative/postoperative documentation (including measurements and photographs), and the occurrence of any major or minor complications were used as the main outcome measures. Approval was obtained from the IRB (Institutional Review Board) of the University of Hawaii. All patients included for the sutureless procedure demonstrated an MRD-1 of 0-4 mm ptosis and a significant lid elevation of at least 1 mm for five minutes following installation of 2.5% phenylephrine hydrochloride ophthalmic solution. Additionally, patients had visual field defects greater than 50% due to ptosis that could be improved by taping the eyelid were included. These patients also presented with adequate (> 10 mm) levator function. Only acquired ptosis was included for this trial. The degree of ptosis was determined through the slit lamp examination (figure 2-5) and external photos. The amount of deviation from the normal MRD-1 of above 4 mm was measured (figure2). Patients with 0-4mm of deviation were included for the trial. One drop of 2.5% phenylephrine hydrochloride ophthalmic solution was installed in the upper conjunctiva beneath the upper lid after the patient was instructed to tilt his or her head back and upper lid was held upward by surgeon. This technique helped to achieve maximum responsiveness to the phenylephrine to Muller's muscle and was used to assess the potential benefit of the Fasanella Servat procedure.

RESULTS

Müller's muscle-conjunctival resection with cautery of Chen's modified sutureless Fasanella-Servat was performed on 62 eyes and 47 patients. Neither sutures nor fibrin sealant was used in any of the operations. Of these patients, 31 underwent unilateral correction, while the remaining 15 underwent bilateral correction with symmetry. There were 23 males and 24 females and the mean age was 73 years old (table 1). The majority of who were of Asian descent. The follow-up period varied from one week to 10 years and was conducted in a private practice office setting. No major complications, including, but not limited to, tarsal buckling or wound dehiscence, were observed. In one case, slight pain and irritation from a mild abrasion were noted on the day following the procedure. Elderly patients with superficial corneal disease typically may present with this condition, and it resolves itself within one to two days of treatment. Beyond one mild abrasion no other minor complications were noted (table 2). Of the 62 eyes included in this study, good lid position and successful, which was defined as MRD-1 above 4mm, was obtained in 59 eyes (95.1%, table 4, patients photo in Fig 1,6,7). The mean post-operative MRD-1 was 3.35mm (ranging from 2-4 mm) with a mean improvement of 2.69 mm (Table 3) in one to three weeks. The remaining three eyes demonstrated improvement in lid position, though not to the desired extent. Postoperatively, all eyes appeared symmetrical. Symmetry was defined as MRD1 of each eyelid within 0.5 mm.

DISCUSSION

The original motivation for performing the sutureless variation of the Fasanella-Servat procedure was to reduce the incidence of complications that accompanied the placement of sutures. Luring's original trial 37 years prior, demonstrated the sutureless technique to be effective, but it contained a limited number of patients and inadequate follow-up for a satisfactory conclusion. Recent studies have continued to demonstrate the effectiveness of the sutureless variation of the procedure.^{7, 8, 12} However, some used sutures to assist in the procedure, while others suggested that the sutureless procedure necessitates a fibrin sealant to prevent complications.^{8,12} While these studies have adopted the fibrin sealant as a part of the sutureless Fasanella-Servat operation, they acknowledge its potential drawbacks,⁹ including its cost (\$150 per eye) and a slight risk of disease transmission.

A potential limitation of this trial was that because of its retrospective nature, the follow-up time was not standardized. Thus, some patients experienced a longer follow-up period than others did. Another limitation is that a single surgeon presented the surgical techniques and outcomes without a control group. However, the outcomes and efficacy of this technique without using any sutures and sealant matched other similar procedure with less complication in the long term. (table4)

Introduction of this new modified technique to more surgeons to perform on their patients to obtain more case results will further validate its benefits in the future.

CONCLUSION

The modified sutureless Fasanella-Servat technique utilizing cautery for wound closure without any suture or sealant demonstrated as efficient, safe and effective as previous described sutureless Fasanella-Servat technique (table4) in this long term trial. However, in comparison, the procedure was faster, safer and economical.

REFERENCES

1. Custer PL.(2009) Blepharoptosis. In: Yanoff M, Duker JS, Augsburger JJ, et al, ed. *Ophthalmology*. 3rd ed. United States: Elsevier, 2009: 1397-1403.
2. Vagefi MR, Sullivan JH. (2011) Lids and Lacrimal Apparatus In: Riordan-Eva P, Cunningham ET Jr. *Vaughan and Asbury's Ophthalmology*. 18th ed. United States: McGraw-Hill, 2011.
3. Thean JH. McNab AA. (2004) Blepharoptosis in RGP and PMMA hard contact lens wearers. *Clin Exp Optom* 2004; 87:11-4.
4. Fasanella RM, Servat J. Levator resection for minimal ptosis (1961): another simplified operation. *Arch Ophthalmol* 1961; 65:493-6
5. Beard C. (1970) Blepharoptosis repair by modified Fasanella-Servat operation. *Am J Ophthalmol* 1970; 69:850-7
6. Lauring L. (1977) Blepharoptosis correction with sutureless Fasanella-Servat operation. *Arch Ophthalmol* 1977; 95:671
7. Gupta VP, Aggarwal R, Mathur SP.(1992) Blepharoptosis repair by modified sutureless Fasanella-Servat Operation (F.S.O)--a large series of 50 cases. *Indian J Ophthalmol* 1992; 40:869.
8. Foster JA, Holck DE, Perry JD, et al.(2006) Fibrin sealant for Müller muscle-conjunctiva resection ptosis repair. *Ophthal Plast Reconstr Surg* 2006; 22:184-7.
9. Czyz CN, Rich NE, Foster JA, et al. (2011) Comparison of postoperative eyelid position using fibrin sealant versus suture for wound closure in Müller's muscle–conjunctiva resection ptosis repair, *Plastic and Reconstructive Surgery* 2011; 128:423-430.
10. Betharia SM, Grover AK, Kalra BR. (1983) The Fasanella-Servat operation: A modified simple technique with quantitative approach. *Br J Ophthal* 1983; 67:58-60
11. Schaeffer AJ.(1977) Congenital and Acquired Ptosis Surgical Techniques In: Silver B, ed. *Ophthalmic Plastic Surgery*. 3rd ed. United States: American Academy of Ophthalmology and Otolaryngology, 1977: 133-5.
12. Foster JA, Holck DE, Perry JD, et al. (2006) Fibrin sealant for Müller muscle-conjunctiva resection ptosis repair. *Ophthal Plast Reconstr Surg* 2006; 22:184-7.
- 13.Samimi DB, Erb MH, Lane CJ, Dresner SC, (2013)The modified Fasanella- Servat procedure: description and quantified analysis, *Ophthal Plast Reconstr Surg* 2013 Jan-Feb; 29(1)30-4

Table 1: Demographic Characteristic of Patients

	Left eye (N=19)	Right eye(N=12)	Both eye (N=15)	Total (N=47)
Age (years)	72.4±10.0	70.8±11.4	76.4±7.2	73.3±9.7
Gender (Male: Female)	7:12	5:7	10:5	23:24

Table 2: major and minor complications

	major	Excessive bleeding	infection	Cornea abrasion	tarsal buckling	Wound dehiscence	ecchymosis,	entropion	total
N &% Eyes in this procedure	0/62 0%	0/62 0%	0/62 0%	1/62 1.6%	0/62 0%	0/62 0%	0/62 0%	0/62 0%	1/62 1.6%

Table 3: pre-op mean MRD1 to post-op mean MRD1 and the improvement to lift the upper eye lid for the efficacy of the procedure

	Pre-op, N=62	Post-op, N=62	Improvement to lift the upper eye lid, N=62
Mean MRD1,N=62	0.66 mm (range 0-2mm)	3.35mm (range 2-4mm)	2.69mm

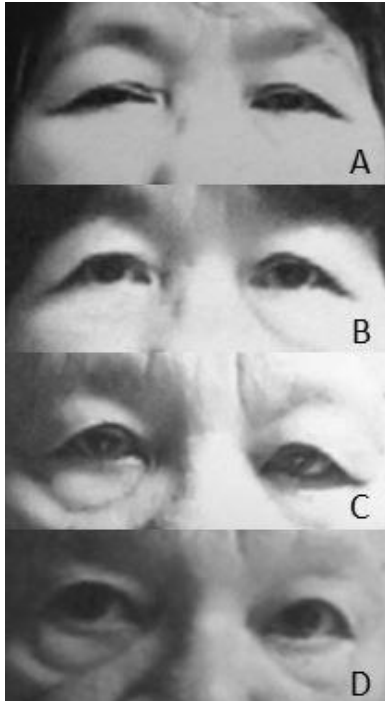
MRD1: The distant between center pupil cornea light reflex to upper lid margin: The less the distant indicate more ptosis. The mean correction was 2.69mm for the ptosis correction to lift the drooping lid

Table 4: Comparison between four modified sutureless Fasanella- Servat procedures

	Year (follow up)	cases	Successful rate	Complication rate	Fibrin sealant	Suture to assist in surgery
Chen	2004-2013(10 years)	62	95.1%	1.6%	none	none
Foster	2006 (45 weeks)	53	98%	2%	yes	none
Gupta	1992 (1 year)	50	94%	10%	none	yes
Lauring	1977	12	92%	17%	none	yes

Fig 1: Preoperative and postoperative photographs display the long-term effectiveness of the Chen's modified sutureless Fasanella-Servat procedure: A) Preoperative; B) Postoperative on Patient 1, two years after surgery; C) preoperative; and D) postoperative on Patient 2, five years after surgery.

Patient #1



Patient #2

Figure 2: Normal eyelid position: MRD1 > 4mm

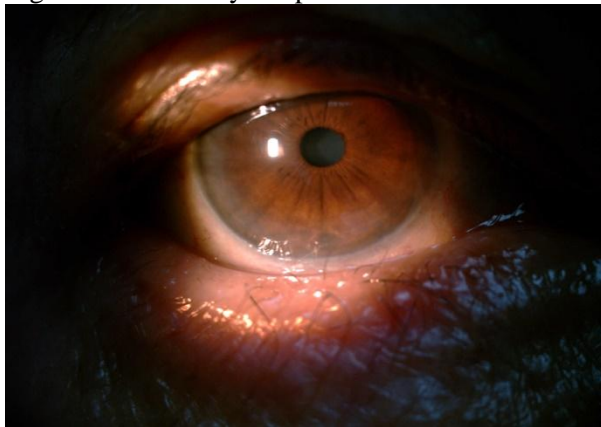


Figure 3: Moderate Ptosis, MRD1=2mm

Figure 4: severe Ptosis MRD1=1mm

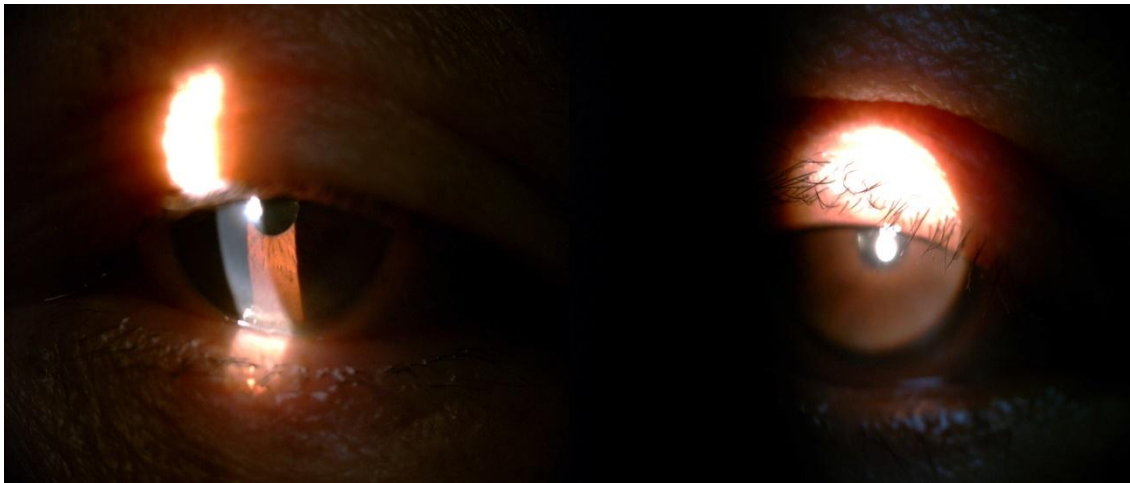

Figure 5: severe ptosis MRD1=0

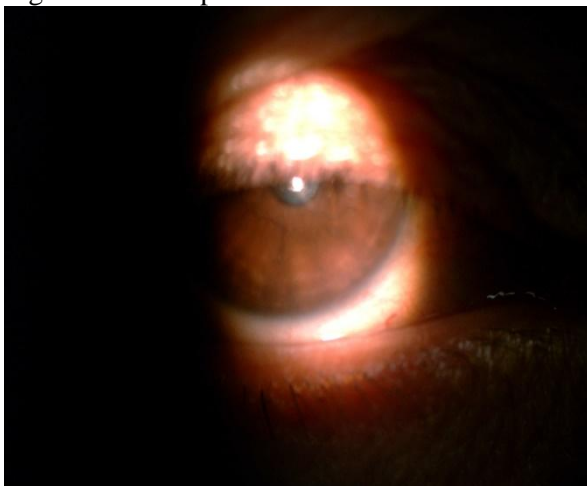


Figure 6: Patient 3: pre-op left eye, post-op left eye, 4mm improvement

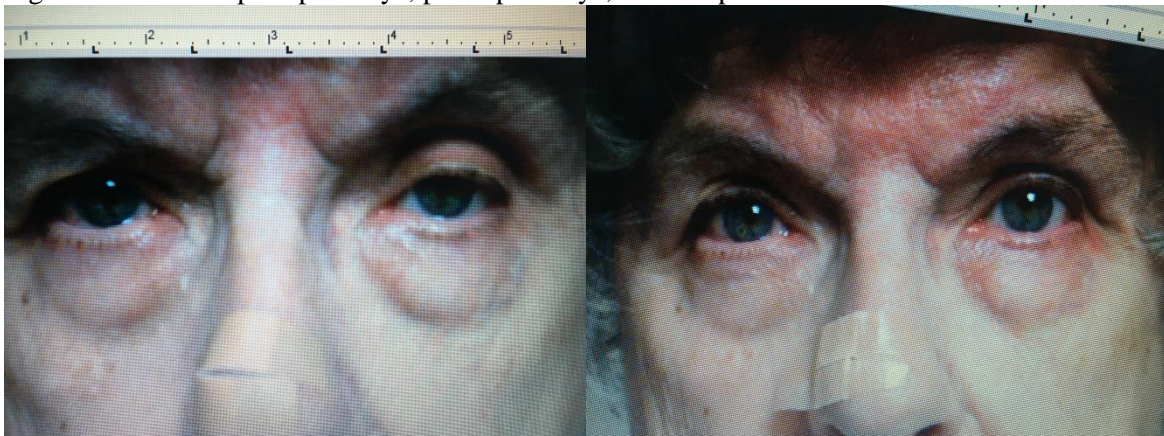


Figure 7: Patient 4: Left eye pre-op and post-op, 4mm improvement

